

## JCO-Online Copyright 2011

# Adjuncts to Bioprogressive Therapy: A Palatal Expansion Appliance for Non-Compliance Therapy

VOLUME 25 : NUMBER 08 : PAGES (491-497) 1991

JAMES J. HILGERS, DDS, MS

Class II malocclusions are virtually impossible correct without expanding the upper arch. The very etiology of Class II malocclusion implies a narrow upper arch, mesially rotated upper molars, blocked-out upper cuspids, and a tapered anterior archform. If the upper model of a Class II case is placed over the lower model in a Class I relationship, it becomes clear that the malocclusion is accompanied by maxillary deficiency, with the posterior segments in crossbite ([Fig. 1](#)).

### The Need for Expansion

My view is that early expansion of the maxilla, as a prelude to orthodontic tooth movement, serves to unlock the Class II malocclusion in a way that makes the rest of the correction easier. Without this pre-emptive expansion, the lower arch can be gradually constricted during treatment. A primary cause of lower second molar impaction is the lingually uprighted lower first molar that has been narrowed by the inclined planes of the unexpanded upper arch.

Haas popularized the concept of the palatal appliance that produces a predominantly orthopedic expansion of the maxilla. This rigid appliance delivers a heavy expansion force through a midpalatal jackscrew. Because the main buttresses to the maxilla are the posterior sutural attachments, its expansion is more noticeable in the anterior region.

Ricketts modified the Coffin-spring appliance into a "W" or quad-helix device that allows outward tipping or warping of the alveolar processes by means of differential activation. It also permits a positive molar distal rotation that can sometimes move the upper molars back by using their large lingual roots as anchorage in the rotational process. This phenomenon was also employed by Goshgarian in his transpalatal bar.

The palate-borne appliance has the advantage of rigidity and accentuation of orthopedic movement. The spring-type appliance offers flexibility, some degree of midpalatal disjunction, and the potential for upper molar rotation, archform changes, and outward tipping of the alveolar processes. Both sets of advantages are beneficial in most Class II, division 1 or 2 cases.

### The Need for Compliance

Correction of Class II malocclusion is highly dependent on patient cooperation-whether with headgear, functional appliances, or elastics. There's the rub: many orthodontists report frequent non-compliance in these areas, as the recent popularity of Pace springs, magnets, [Jasper Jumpers](#), and fixed [Herbst](#) appliances would attest.

This article will introduce a hybrid maxillary expansion appliance that can correct as many as half of all buccal-segment Class II cases, with minimal reliance on patient cooperation. It provides the advantages of both the rigid midpalatal disjunction and the flexible alveolar tipping types of appliances.

### Appliance Design and Fabrication

Before activation, the Hilgers Palatal Expander consists of two molar bands with soldered horizontal helices and an acrylic plate with embedded jackscrew ([Fig. 2](#)). The anterior extensions of the wire serve as bonded occlusal rests on either the first bicuspids or the first deciduous molars.

The helices serve to rotate and distalize the upper molars, using the soft-tissue palate as anchorage in much the same way that a large Nance pad would act as intraoral anchorage. The jackscrew produces an orthopedic midpalatal disjunction.

The appliance is thus able to achieve changes in arch width and form, as well as distal rotation and movement of the upper first molars. It also saves upper "E" space, creates room for erupting cuspids, and, when properly utilized, anchors the molars during upper retraction.

To fabricate the appliance, first fit bands snugly to the upper first molars. These bands should have single molar tubes (not headgear tubes), because the upper arch will be bonded and the initial archwire will be placed *before* the expansion appliance is completely removed, taking advantage of the space created in the buccal segments.

Place the molar bands carefully in an alginate impression, lute them in place with sticky wax, and pour a working model.

Bend an .036" stainless steel wire so that the helix is in the same horizontal plane as the molar band ([Fig. 3A](#)). This will help prevent unwanted extrusion of the molars.

Extend the wire at a right angle from the helix, approaching the palate, and curve it up to create a rest on the occlusal surface of

either the first bicuspid or the first deciduous molar ([Fig. 3B](#)). Make sure that the wire extending out of the acrylic up to the bicuspid is at least 2mm away from the palate, to avoid tissue impingement when the screw is activated. Flatten the occlusal rest slightly with a heatless stone.

Solder the mesial extension of the helix to the mesiolingual portion of the molar band. Thin the solder at the contact point to prevent interference with the adjacent tooth as the molar rotates ([Fig. 3C](#)).

Add the acrylic and jackscrew. Round the edges of the acrylic, keeping it several millimeters away from the easily compressed lingual cuff of tissue around the buccal teeth.

### Appliance Preactivation

Three basic movements will assure proper preactivation of the appliance for molar rotation and distal movement.

First, use a headgear plier to twist the molar bands distally around the horizontal helices, incorporating approximately twice the amount of rotation needed ([Fig. 4A](#)). When the appliance is cemented, about half of this rotation will be lost because of spring compression.

Second, constrict the molar bands with the plier, placing a lingual bend in the vertical portion of the wire that extends out of the acrylic ([Fig. 4B](#)). This ensures that the molar rotation will occur around the long axis of the tooth, without overexpansion. Otherwise the molars may be moved into buccal crossbite before midpalatal disjunction can be achieved. To compensate for tipping, flatten the helices back to horizontal.

Third, to make sure that the occlusal rests fit into the fossae of the anterior teeth, hold the rotation loop with the headgear plier and bend the appliance slightly palatally to place a minor tipback force on the molars ([Fig. 4C](#)). This activation may seem inconsequential, but I have found that without it, once the appliance is cemented to the molars, the anterior portion will not touch the palate and the occlusal rests will no longer fit into the fossae of the bicuspid.

For an indication of the amount of molar rotation and distal movement to be expected, place the preactivated appliance over the working model ([Fig. 4D](#)).

Before cementing the appliance in place, remove small amounts of acrylic from the corners to avoid tissue impingement as expansion occurs ([Fig. 5](#)). As with any palatal appliance, it is crucial for patient comfort that the acrylic portions be rounded and smoothed.

### Appliance Placement and Activation

Place cement in the molar bands and seat the appliance one molar at a time. As soon as the initial band has been seated, the preactivated molar rotation will cause the appliance to drop back into the soft palate ([Fig. 6A](#)). Stabilize the appliance with a finger and bring it forward immediately to prevent the gag reflex.

With the appliance in its correct palatal position, compress the opposite molar band and fit it loosely over the tooth ([Fig. 6B](#)). The key is to get the appliance approximately in place without taking out the preactivation. After initial placement, seat each molar band in its final position with a band driver or band biter.

Etch the bicuspid, and use a syringe to place a small amount of adhesive over the occlusal rests, bonding them into the fossae ([Fig. 6C](#)).

Smooth out the adhesive with a sealant mix on a foam mini-sponge ([Fig. 6D](#)). Although banding the appliance to the bicuspid (or first deciduous molars) would make it more rigid, it would be virtually impossible to cement four bands at once.

Because this is a much more active expansion appliance than the rigid, fixed type, the activation of the screw should proceed slowly to minimize patient discomfort and tissue impingement. There will be some initial tenderness due to the molar rotation, so the patient should be told to begin activation when comfortable with the appliance (about five days after cementation). Then the patient should activate the jackscrew one-quarter turn every other day, and should be seen again in two weeks.

The appliance is reactivated until the lingual cusps of the upper buccal segments sit at the top of the buccal incline of the lower buccal segments. It is then stabilized for three months while space is gathered in the buccal segments. The midpalatal jackscrew activation greatly enhances distal movement of the upper molars, especially when they are being moved back against erupting second molars.

### Gathering Space in the Buccal Segments

Expansion of the maxilla and rotation of the molars will produce large amounts of space in the buccal segments. If the molars were severely rotated before treatment, it would not be unusual to see a total space gain of 5mm per side ([Fig. 7](#)).

Rather than simply removing the appliance and allowing the molars to drift forward again, it is quite beneficial to consolidate the space distally during the three-month stabilization period. This is done by stabilizing the jackscrew and then severing the wires to

the bicuspid ([Fig. 8A](#)). The acrylic plate acts as an intraoral anchorage unit against which the buccal segments can be retracted.

A heavy-wire cutter or a high-speed bur can be used to sever the wire. It is more comfortable for the patient if the adhesive is removed from the bicuspid and the palatal portion of the wire is lifted slightly with a scaler before the wire is cut.

The upper arch is then completely bonded with brackets, and the buccal segments are retracted to the molars with elastic chain or, if the upper incisors are impinging on the lower incisors in a deep bite, with push-coil springs. This approach has the added advantages of advancing the upper incisors, freeing the lower arch for banding, and creating adequate space for erupting upper cuspids ([Fig. 8B](#)).

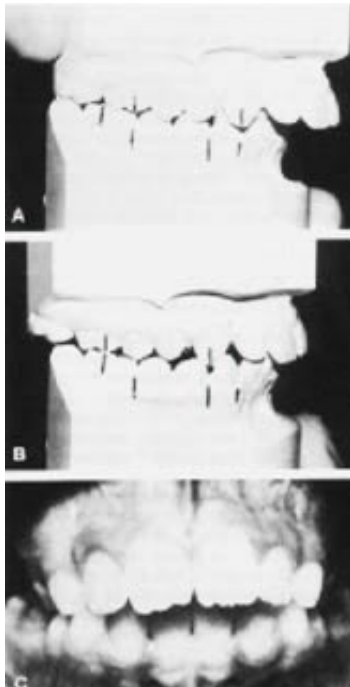After the three-month stabilization period, remove the appliance, reband the molars, and continue with fixed appliance treatment.

### Conclusion

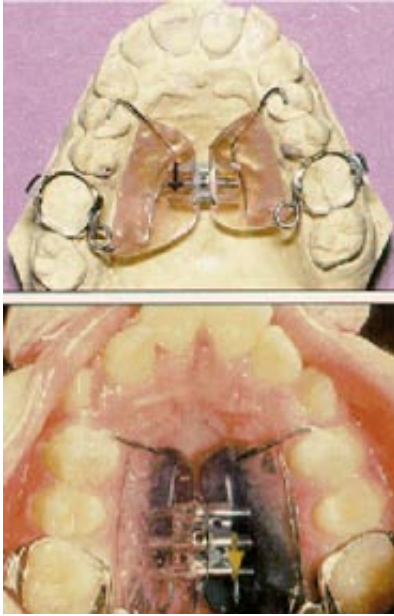
The Hilgers Palatal Expander is a hybrid appliance that uses the best features of the flexible quad-helix, the rigid palatal Nance button, and the rigid midpalatal disjunction appliance. It has proven especially effective in the treatment of Class II malocclusion with concomitant maxillary deficiency.

The appliance can orthopedically expand the maxilla, change archform, rotate and distalize the upper first molars, create room for erupting cuspids, gather space in the upper buccal segments, and unlock the anterior occlusion--all without relying on patient compliance.

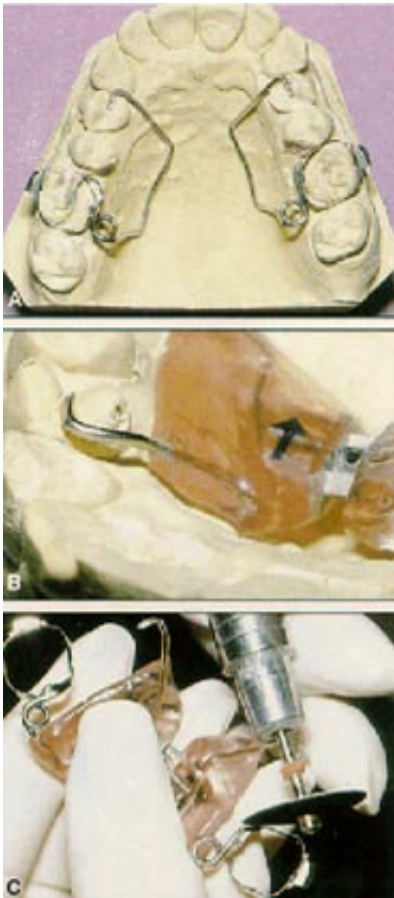
### Figures



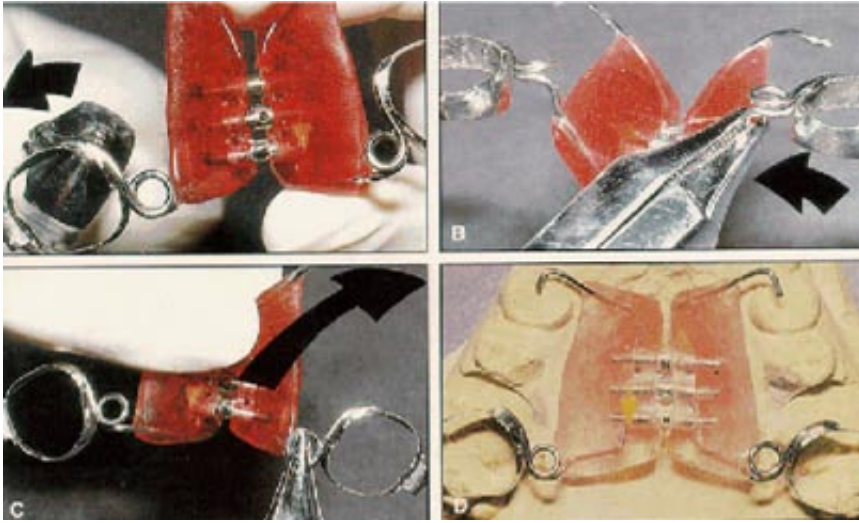
**Fig. 1** A. Models in Class II position (patient centric). B. When upper model is moved to Class I relationship with lower model, maxillary deficiency and crossbite are apparent. C. Lower arch is constricted by lingual tipping of upper buccal segments in Class II malocclusion.



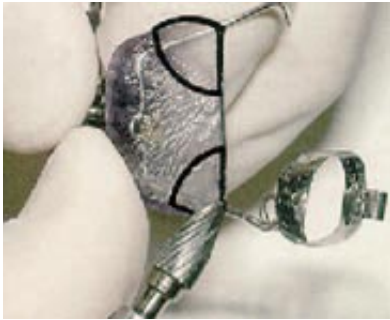**Fig. 2** Hilgers Palatal Expander.



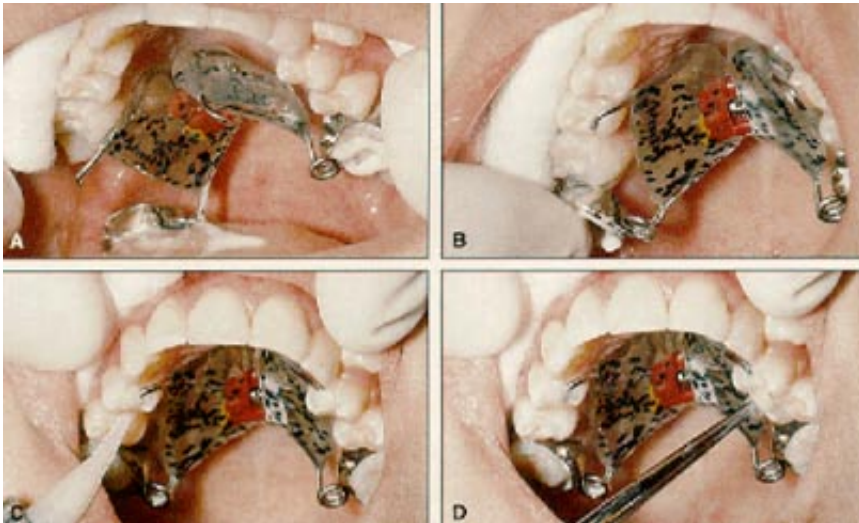
**Fig. 3** Appliance fabrication. A. Horizontal helices bent from .036" stainless steel wire and soldered to mesial of molar bands. B. Wire extending anteriorly from acrylic is curved up to form occlusal rest on first bicuspid or deciduous molar, keeping wire at least 2mm away from palate. C. Solder joint is thinned at mesial contact point to prevent rotational interference.



**Fig. 4** Preactivation steps. A. Headgear plier engaged at mesial upper molar solder joint. Band is twisted distally around helix to incorporate twice the amount of rotation needed. B. Plier placed on vertical portion of wire directly below helix and twisted lingually to constrict molar band. C. Helix held with plier and appliance bent slightly palatally to place minor tipback force on molar band. D. Preactivated appliance checked against working model to anticipate molar rotation and distal movement.

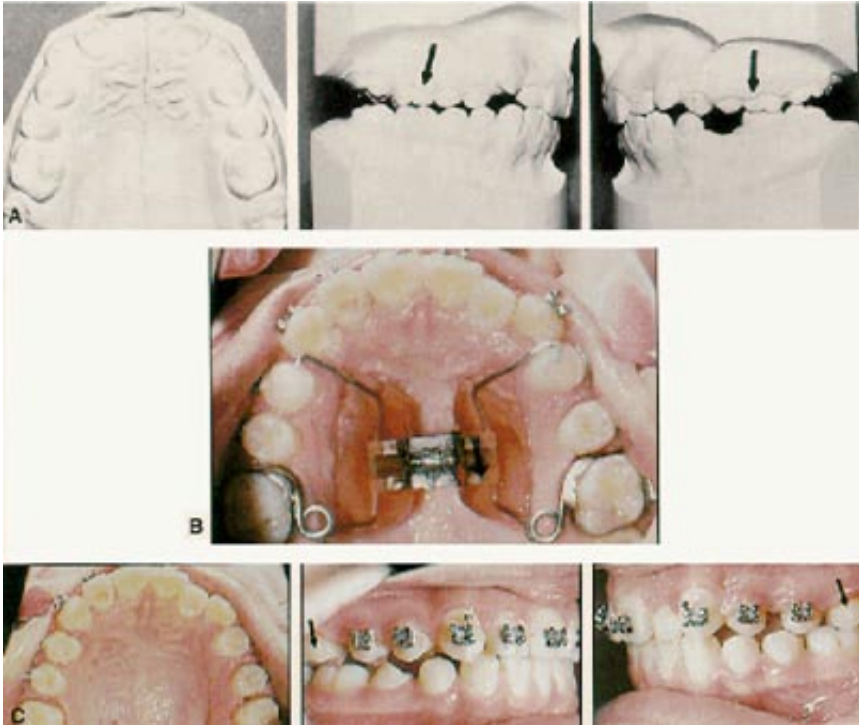


**Fig. 5** Small amount of acrylic removed from four corners of appliance on palatal side to keep acrylic away from compressible tissue. All acrylic should be rounded and smoothed for patient comfort.

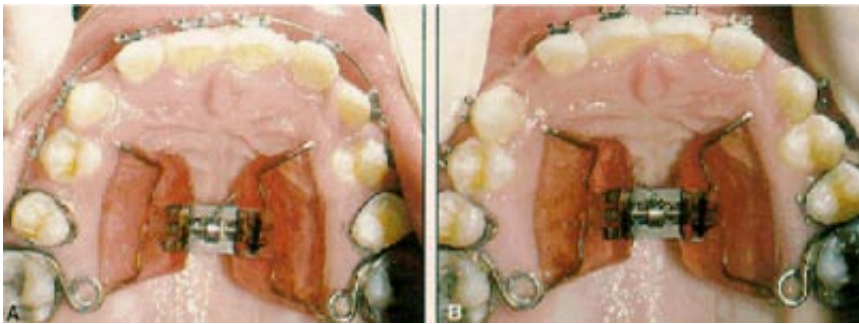


**Fig. 6** Appliance cementation. A. As soon as initial molar band is seated passively, remainder of appliance drops toward soft palate. B. Clinician must quickly move opposite molar band into position. C. Occlusal rest bonded into fossa of first bicuspid. D. Adhesive smoothed with sealant mix on foam mini-sponge.





**Fig. 7** A. Patient before treatment. Note Class II molar relationship. B. Expansion appliance after three-month stabilization period. C. Immediately after appliance removal. About 10mm of space was created in buccal segments, with no attempt to consolidate space distally. Note Class I molar relationship.



**Fig. 8** A. Anterior wire debonded from bicuspids and severed from appliance. B. After distal consolidation of buccal spaces with elastic chain.

## Footnotes

1. Jasper Jumpers, Trademark of American Orthodontics, 1714 Cambridge Ave., P.O. Box 1048, Sheboygan, WI 53082.
2. Herbst, Registered trademark of Dentaurem, Inc., 2 Pheasant Run, Newtown, PA 18940.