

# Correction of severe obstructive sleep apnea with bimaxillary transverse distraction osteogenesis and maxillomandibular advancement

R. Scott Conley<sup>a</sup> and Harry L. Legan<sup>b</sup>

Nashville, Tenn

Obstructive sleep apnea (OSA) can be a debilitating, even life-threatening, condition. The most favorable treatment for patients with OSA is multidisciplinary care by a team that represents various dental and medical disciplines. Prescribed therapies might include weight loss, behavior modification, oral appliances, soft tissue surgery, skeletal surgery, or some combination of approaches. When orthognathic surgery has been used, often only the anteroposterior dimension is addressed, and the transverse dimension is overlooked. The treatment presented here demonstrates the important role that transverse expansion of the maxillary and mandibular arches can have for patients with severe OSA. An initial stage of maxillary and mandibular transverse distraction osteogenesis was performed, followed immediately by fixed orthodontic treatment. After appropriate orthodontic alignment, leveling, and coordination, a second surgical stage consisting of maxillary and mandibular advancement was performed. Marked enhancements in occlusion and facial morphology, and a profound improvement in the OSA, were obtained. (*Am J Orthod Dentofacial Orthop* 2006;129:283-92)

**O** bstructive sleep apnea (OSA) reportedly affects between 2% and 4% of the population.<sup>1</sup> Middle-aged, overweight men comprise a significant portion of this group.<sup>2</sup> Several forms of treatment are available for these patients, including weight loss, behavior modification (ie, changing sleep position, decreasing alcohol consumption), continuous positive air pressure, soft tissue surgery, and orthognathic surgery.<sup>3-7</sup>

Distraction osteogenesis to advance the maxilla and the mandible has been used for more than a decade in the treatment of OSA. Recently, transverse distraction osteogenesis has been used to widen the mandible and the maxilla.<sup>8,9</sup> Some studies in adolescents have demonstrated that rapid palatal expansion can have a beneficial effect on the nasorespiratory pattern.<sup>10</sup> Maxillary transverse distraction osteogenesis has the advantage that not only is the maxillary dentoalveolus widened, but also the floor of the nose. A recent article described a significant reduction in respiratory distur-

bance index (RDI) values from widening the maxilla alone.<sup>11</sup>

Expanding the maxilla and the mandible combined with orthognathic surgery to advance the mandible and the maxilla was successful for the patient whose treatment is presented here. This case report demonstrates the usefulness of bimaxillary transverse distraction osteogenesis in the treatment of OSA.

## HISTORY AND DIAGNOSIS

The patient, a 59-year-old white man, came to the Sleep Center at Vanderbilt University Medical Center; his chief complaints were excessive daytime sleepiness, significant snoring that disturbed his spouse, and a feeling that he was never fully rested. He underwent overnight polysomnography and was diagnosed with severe chronic OSA. His RDI was 44.8; scores greater than 30 are considered severe and potentially life threatening. His body mass index was 28, indicating that he was moderately overweight. He had previously been treated with a continuous positive air pressure machine but did not use it consistently because it was bulky, noisy, and left him feeling "dried out." He said he wanted a cure, not a crutch, and was therefore seeking alternative forms of treatment.

He was referred to the orthodontic clinic, where a clinical examination showed a Class II Division 1 malocclusion (Figs 1-4). Both dental arches were severely constricted but especially the mandibular arch, which had

From the Division of Orthodontics, Vanderbilt University Medical Center, Nashville, Tenn.

<sup>a</sup>Assistant professor.

<sup>b</sup>Professor and director.


Reprint requests to: R. Scott Conley, Vanderbilt University Medical Center, Division of Orthodontics, 1500 21st Ave South, Suite #3400, Nashville, TN 37212; e-mail, scott.conley@vanderbilt.edu.

Submitted, August 2005; revised and accepted, November 2005.

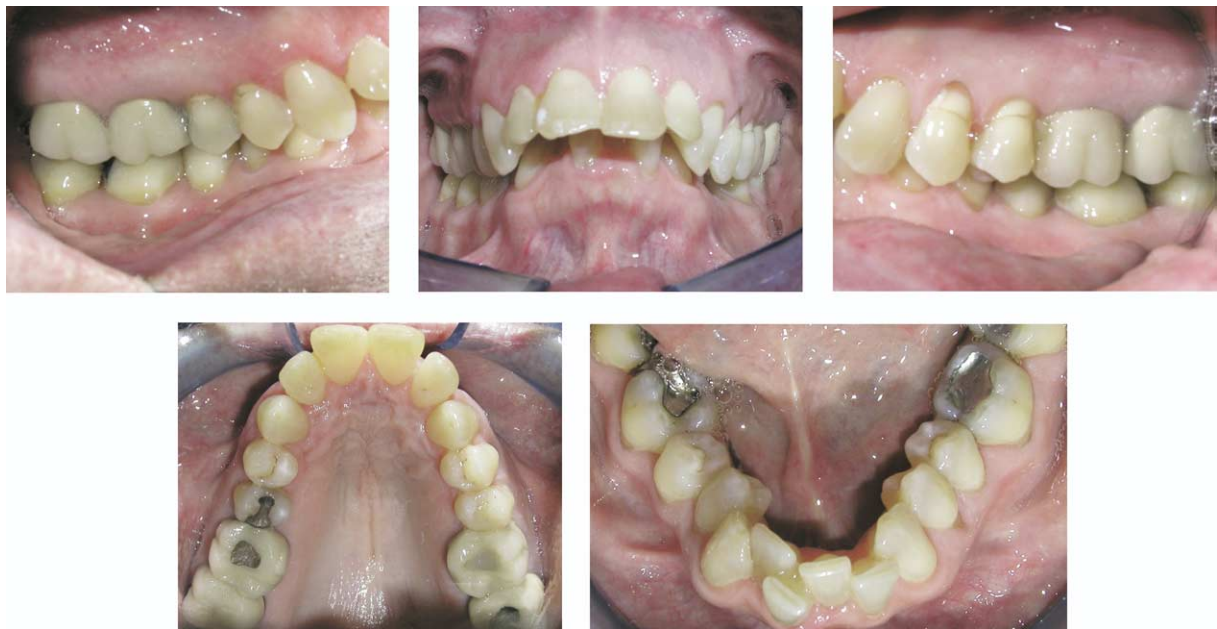0889-5406/\$32.00

Copyright © 2006 by the American Association of Orthodontists.

doi:10.1016/j.ajodo.2005.11.029



**Fig 1.** Pretreatment extraoral photographs.

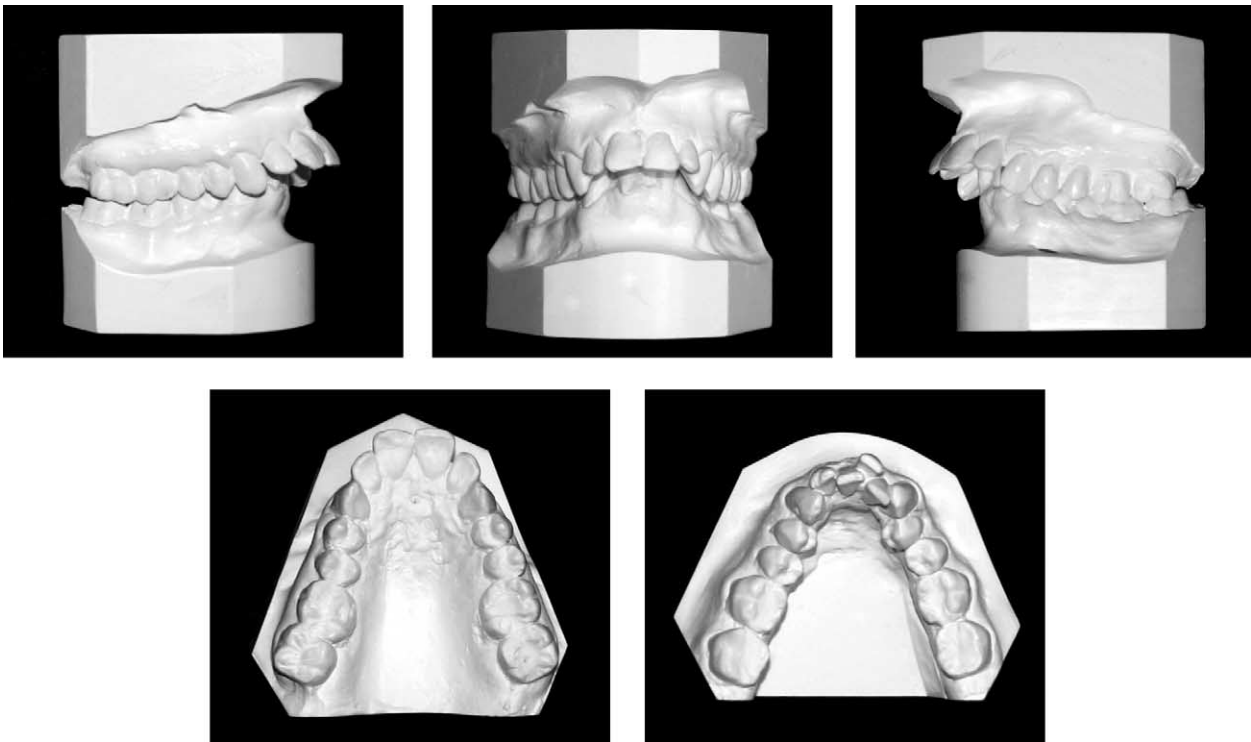


**Fig 2.** Pretreatment intraoral photographs.

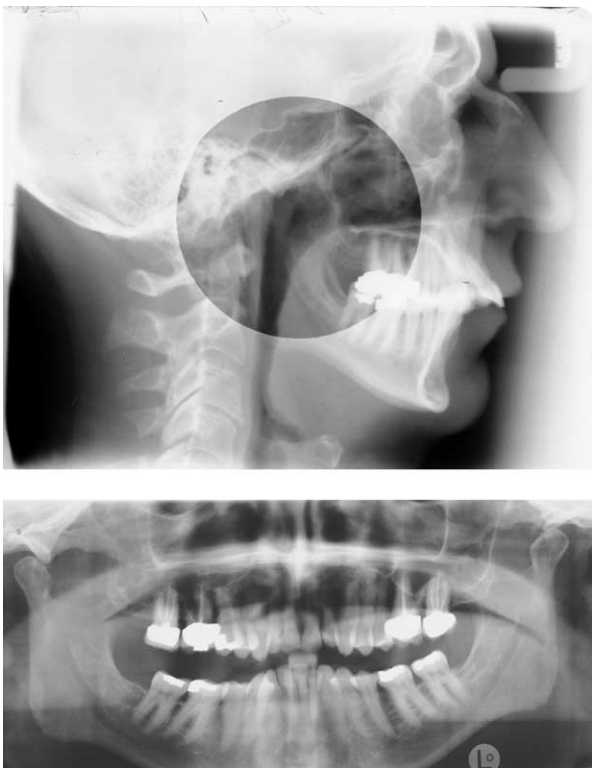
an intercanine width of only 12 mm. The overbite was 100% and was palatally impinging with an excessively deep mandibular curve of Spee. Severe mandibular arch length deficiency and mild maxillary arch length deficiency were present. The maxillary tooth-to-lip relationship was normal for a man his age, with essentially no incisal show at rest and full crown display on smiling. Some mild gingival recession was present in the maxillary and mandibular buccal segments. He also had many Class V composite resin restorations. Radiographically, the entire maxillary and mandibular dentitions were present with the exception of the third molars. Mild localized bone

loss was observed, but no active periodontal disease was present. Cephalometrically, the maxilla and the mandible were retrusive, the mandible more so than the maxilla. The patient was diagnosed with severe OSA and Class II Division 1 malocclusion with maxillary and mandibular transverse and anteroposterior hypoplasia.

Facially, the soft tissue drape was consistent for a man his age. Some laxity of the skin and muscles of the face was present, producing mild "jowling" and a poorly defined chin-throat angle. The cartilaginous portion of the nose displayed continued growth, also consistent for his age.



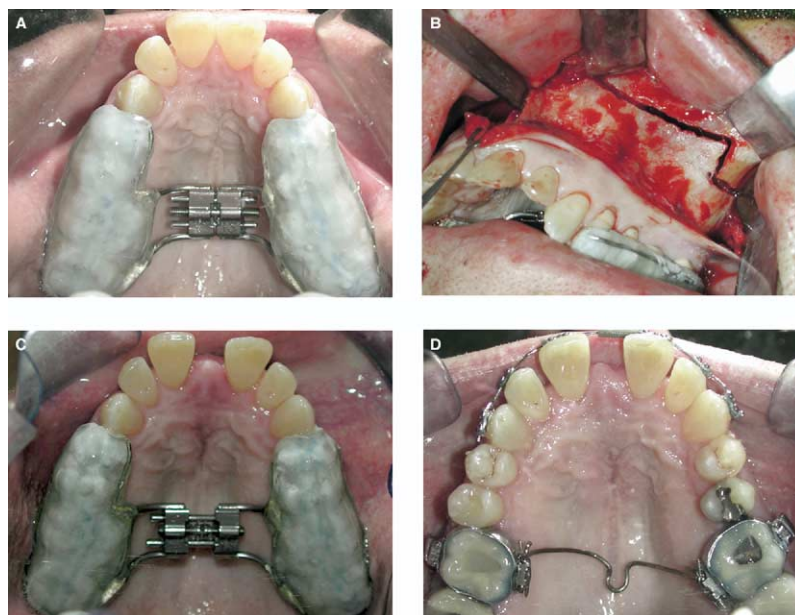**Fig 3.** Pretreatment dental casts.



**Fig 4.** Pretreatment lateral cephalometric and panoramic radiographs.

#### **TREATMENT OBJECTIVES**

The main treatment objective was to resolve the OSA. The patient was less concerned about his malocclusion but was willing to do whatever was necessary to correct his OSA. To address the maxillary and mandibular transverse and anteroposterior hypoplasia, a 2-stage surgical orthodontic approach was presented. The first stage of surgery included mandibular symphyseal distraction osteogenesis to widen the mandible and maxillary transverse distraction osteogenesis to widen the maxilla. The mandibular widening would provide the space required to align the dentition. The transverse expansion of the mandible would also create a larger oral volume to accommodate the tongue and reduce the chance of the tongue causing oropharyngeal obstruction during sleep. The concomitant maxillary transverse distraction osteogenesis would resolve the severe maxillary constriction and accommodate the subsequent surgical mandibular advancement. The second stage of surgery would provide the definitive OSA relief. The maxilla would be advanced approximately 10 mm, with essentially no change in the vertical dimension, and the mandible would be advanced approximately 18 mm.



**Fig 5.** Maxillary distraction. **A**, Bonded maxillary expansion appliance was fabricated because patient had difficult path of draw. **B**, Subtotal LeFort I osteotomy with midline osteotomy performed with osteotome and mallet. **C**, Maxillary expansion. **D**, Maintenance of maxillary expansion with 0.036-in heat-treated stainless steel transpalatal arch.

### TREATMENT ALTERNATIVES

If the only consideration for this patient had been orthodontic, the treatment plan could have included extraction of the maxillary and mandibular first premolars. Extractions would have allowed alignment of the dentition but most likely would not have allowed for the necessary Class II correction. In addition, the dental arches would have been further constricted; thus, the OSA would not have been improved and might have worsened. A second treatment plan might have involved the extraction of 4 first premolars to align the dentition and 2-jaw surgery to resolve the Class II relationship. The surgery would require a 3-piece LeFort I osteotomy with segments created by osteotomies between the canines and the lateral incisors. Simultaneously, the patient would have had a bilateral sagittal split ramus osteotomy to surgically advance the mandible.

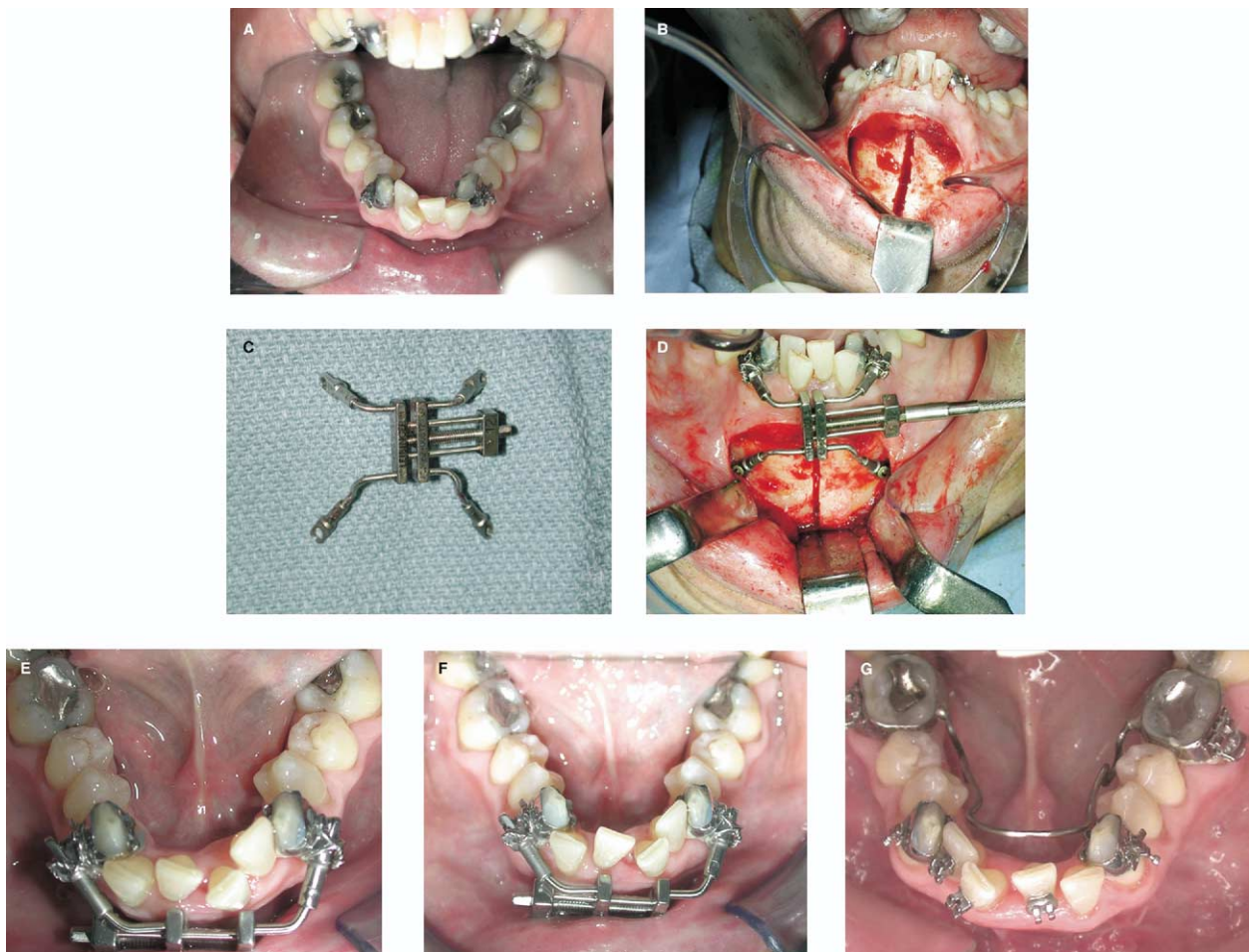
### TREATMENT PROGRESS

Before orthodontic alignment could begin, maxillary and mandibular transverse distraction osteogenesis was necessary (Fig 5). Although the porcelain-fused-to-metal crowns on the maxillary posterior dentition could accommodate an orthodontic band, no common path of draw was present that would allow for seating a standard banded hyrax. As a result, a modified bonded hyrax expansion appliance was fabricated. The expansion

screw was soldered to a 0.045-in stainless steel wire attached to the gingival margin of the facial and palatal surfaces of the maxillary first premolars to second molars bilaterally. Care was taken to have limited acrylic in the palate to minimize pressure and potential vascular constriction of the palatal mucosa during the expansion phase of the distraction. The maxillary osteotomy was similar to the approach described by Bell,<sup>12</sup> with the addition of a 7-day latency period. An incision was made in the maxillary vestibule and carried laterally and posteriorly. A reciprocating saw was used to perform osteotomies on the lateral maxillary and nasal walls. The maxilla was separated from the pterygoid plates of the sphenoid bone with a curved osteotome. Finally, a spatula osteotome and mallet were used to perform the midpalatal osteotomy all the way to the posterior aspect of the hard palate, determined by digital palpation. Care was taken not to perforate or damage the palatal vascular pedicle.

Tooth-borne appliances are often used when performing mandibular transverse distraction osteogenesis. However, in this case, the smallest tooth-borne expansion screw that could accomplish the necessary transverse expansion was too large to fit on the lingual aspect between the canines (Fig 6). As a result, bands were placed on the mandibular canines, and a hybrid mandibular transverse distraction appliance (Leibinger)



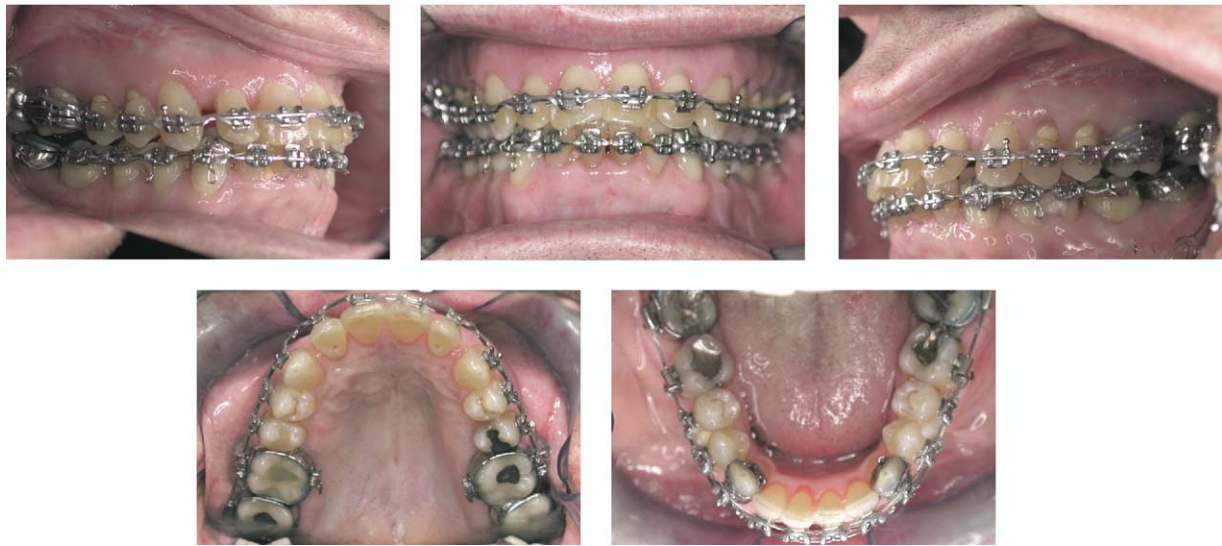

**Fig 6.** Mandibular distraction performed concurrently with maxillary distraction but illustrated separately for clarity. **A-D**, Pretreatment, initial osteotomy, appliance, and stabilized appliance; **E** and **F**, 2 stages during active distraction with stabilized distraction with 0.036-in heat-treated mandibular lingual arch (shown in **G**).

was placed. A horizontal incision was performed on the lower lip approximately 5 mm labial to the depth of the labial vestibule. Careful and gentle tunneling dissection was performed to preserve as much labial gingival attachment as possible. The initial vertical midline osteotomy was performed with a reciprocating saw starting at the inferior border of the mandible. The initial interdental portion of the osteotomy was performed with a 701 bur with copious irrigation to score the mandibular buccal cortex. Completion of the interdental osteotomy was performed with a fine spatula osteotome and gentle malleting. The distraction appliance was attached superiorly to the canines. Inferiorly, the appliance was held in place with 2 monocortical screws. The mucosa was then sutured in place, allowing the 2 inferior arms to remain transmucosally.

A latency period of 1 week was observed. The rate

of distraction was 1 mm per day. The rhythm of distraction was 2 turns (0.5 mm) of the maxillary appliance in the morning and evening, and 1 turn (0.5 mm) of the mandibular distraction appliance in the morning and 1 in the evening. The minimum activation of the mandibular appliance was 0.5 mm. The patient was seen once or twice a week during active distraction. After that, stainless steel ligature ties from the central incisors to the distraction appliance were used to prevent mesial migration of the teeth into the distraction gap. After 3 months, the maxillary and mandibular distraction appliances were removed. In the maxilla, a passive 0.036-in heat-treated stainless steel transpalatal arch was placed immediately. The mandible was slightly overexpanded at the end of distraction, and a lingual arch was not placed for almost 2 months to allow for some slight lingual movement.



**Fig 7.** Two-month postsurgical progress photos. Space between maxillary lateral incisors and canines was intentional and preserved to ensure that well-seated Class I canine relationship could be obtained during maxillomandibular advancement surgery.

Postdistraction, conventional orthodontic therapy was performed to obtain well-coordinated and well-aligned dental arches. There was no attempt to orthodontically correct the Class II relationship, because it would be corrected in the second stage of maxillomandibular advancement surgery. Just before surgery, coordinated  $.017 \times .025$ -in stainless steel surgical wires with hooks were placed. Five hooks were placed on the wire in the maxilla and 1 in the midline, 1 between the central and lateral incisors bilaterally, and 1 between the first and second premolars bilaterally. In the mandible, 4 hooks were placed, 1 between the central and lateral incisors bilaterally and 1 between the first and second premolars bilaterally. Because of the large curve of Spee, the initial crowding, and the desire to extrude the posterior teeth and minimize mandibular incisor proclination, the mandibular arch was not leveled completely presurgically. The postsurgical orthodontic plan included use of lighter mandibular stainless steel arch wires ( $0.018$  or  $0.016 \times 0.022$  in) with elastics run in the midarch against a  $0.019 \times 0.025$ -in stainless steel maxillary archwire. Postsurgical leveling had the advantages of erupting the mandibular dentition into space (air) rather than into occlusal forces and also using the regional accelerative phenomenon described by Frost<sup>13</sup> (Fig 7).

#### TREATMENT RESULTS

A well-intercuspatated Class I molar and canine relationship with increased maxillary and mandibular

basal transverse dimension was obtained (Figs 8-11), but, most importantly, the patient reported a significantly improved level of alertness. His spouse reported fewer disturbances during sleep, and the postsurgical polysomnography showed an RDI of less than 10. The lateral cephalometric superimpositions (Fig 12) show the maxillary and mandibular advancement, but not the significant transverse expansion that was achieved.

#### DISCUSSION

Nonsurgical, 4-tooth extraction treatment would have addressed the orthodontic aspects of this patient's malocclusion. However, in the treatment of OSA, alignment of the teeth is a secondary goal. The primary goals for this patient were to improve the mean oxygen saturation, reduce the RDI, and improve the quality and the quantity of sleep to reduce the debilitating effects of OSA. Constricting the dental arches, as often occurs with orthodontic extractions, could be counterproductive to maximally improving the patient's overall health and orofacial health. Making already constricted arches smaller (both anteroposteriorly and transversely) potentially exacerbates the symptoms and complications of OSA and is therefore generally not recommended. As a result, a treatment plan involving expansion of the arches in all 3 dimensions must be considered as the most viable and beneficial for the patient.

Bimaxillary advancement has been described as an effective surgical treatment for OSA. Some have even






Fig 8. Posttreatment extraoral photographs.

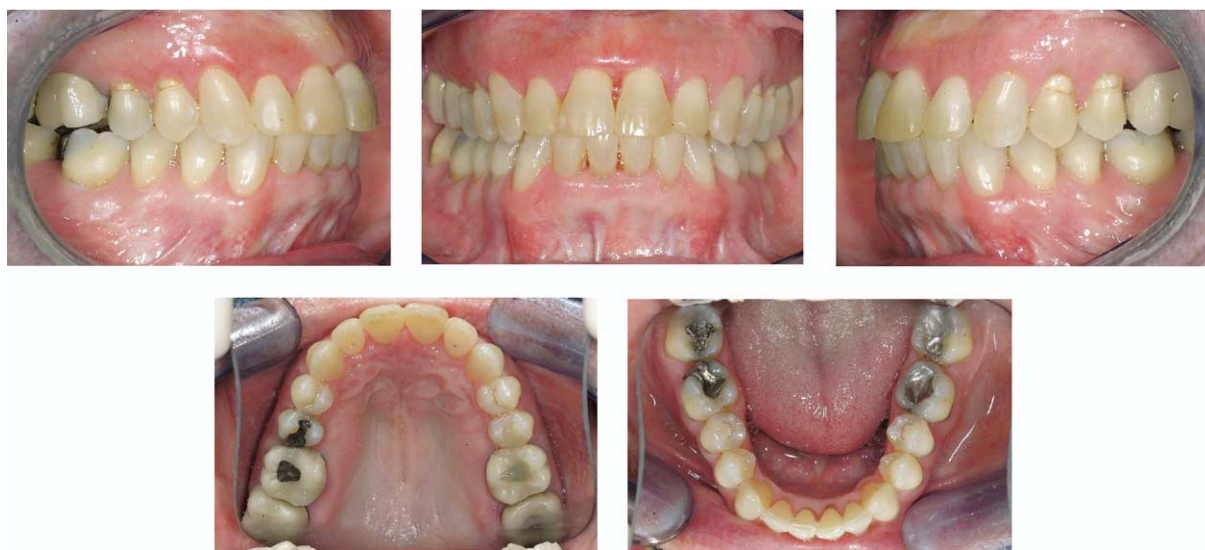

Fig 9. Posttreatment intraoral photographs.

called it a cure.<sup>14</sup> However, few articles discuss the role of the transverse dimension in the treatment of OSA. A recent article attempted to discuss the benefit of maxillary expansion and the subsequent decrease in apneic and hypopneic events, but no patient in that report had a significant pretreatment RDI.<sup>10</sup>

Anatomically, expanding the maxilla produces a larger nasal cavity and theoretically decreases the resistance to nasal airflow. Expansion of the maxilla can be obtained surgically in 2 ways: maxillary transverse distraction osteogenesis or segmental LeFort I osteotomy. Typically, the expansion obtained in the segmental Lefort I is more limited, producing only 5 to 7 mm. Maxillary transverse distraction osteogenesis has been used to produce as much as 12 mm of

expansion. The larger transverse expansion from the distraction allows for a greater nasal cavity volume increase and should reduce the resistance to nasal airflow even more than the segmental LeFort.<sup>15</sup> If the airway is considered a simple tube, as the radius of the tube increases, the resistance to flow decreases exponentially to the fourth power<sup>16</sup> (resistance =  $8L\eta/\pi r^4$ ). Therefore, even small increases in the diameter of the tube (the nasal cavity) can dramatically decrease in the resistance to nasal air flow.

Maxillary and mandibular distraction osteogenesis in the transverse dimension should augment the nasopharynx, the oropharynx, and the nasal cavity. The musculature of the palate and the nasopharynx should expand to some extent during the maxillary expansion.

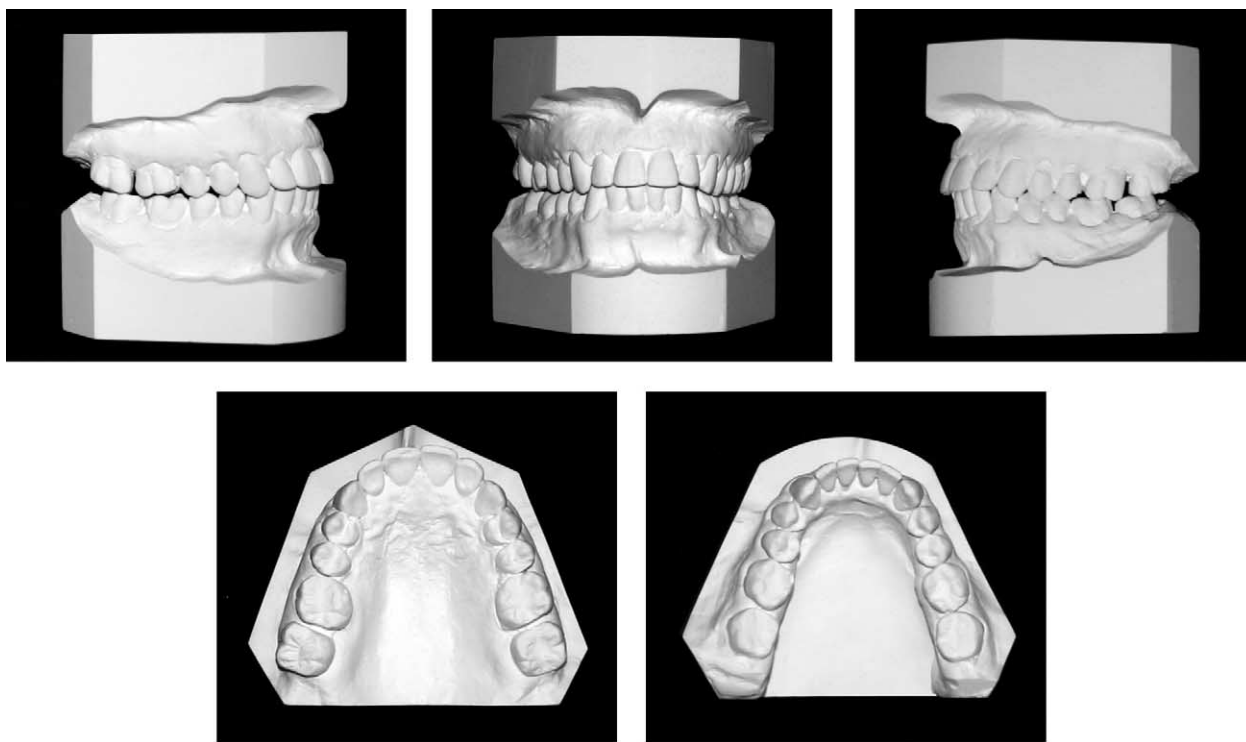


Fig 10. Posttreatment dental casts.

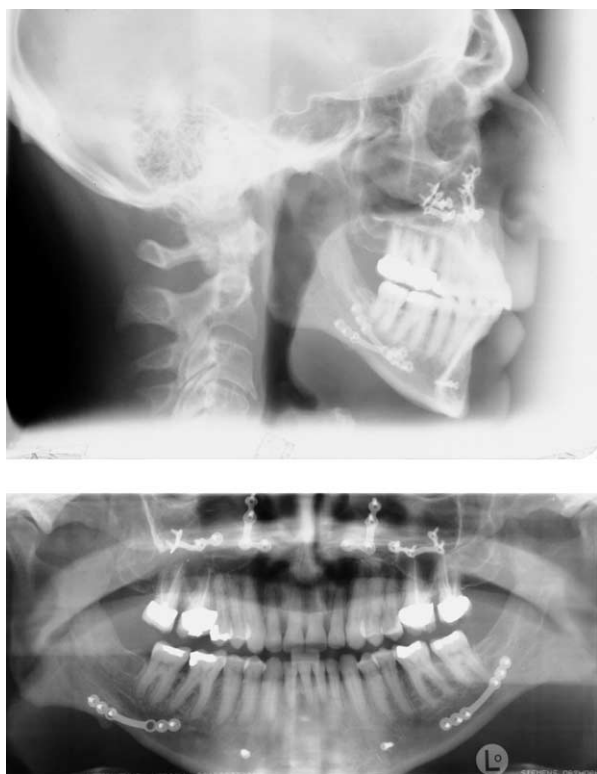


Fig 11. Posttreatment lateral cephalometric and panoramic radiographs.

This would include the tonsillar pillars (palatoglossus and palatopharyngeus muscles) and the musculature of the velum itself (levator veli palatini and tensor veli palatini). Although the mandibular transverse expansion is more dramatic anteriorly, there is also a posterior component to the expansion. This presumably includes the musculature of the oropharynx such as the superior and middle pharyngeal constrictors. Just as small changes in the diameter of the nasal cavity dramatically decrease air resistance, so too expansion of the nasopharynx and the oropharynx would further decrease air resistance. The combined effects of both maxillary and mandibular expansion should be greater than maxillary expansion alone. Furthermore, the ability to predictably expand the mandible allows for greater maxillary expansion because the maxilla and the mandible need to “fit” in the transverse dimension.

When considering expansion, the treatment plan should address both short-term and long-term effects. The expansion achieved from a segmental LeFort I osteotomy not only is of a lesser magnitude, but also is not as stable as expansion achieved from maxillary transverse distraction osteogenesis.<sup>17,18</sup> In addition, segmental maxillary surgery is technically more difficult with a higher risk of complications than maxillary



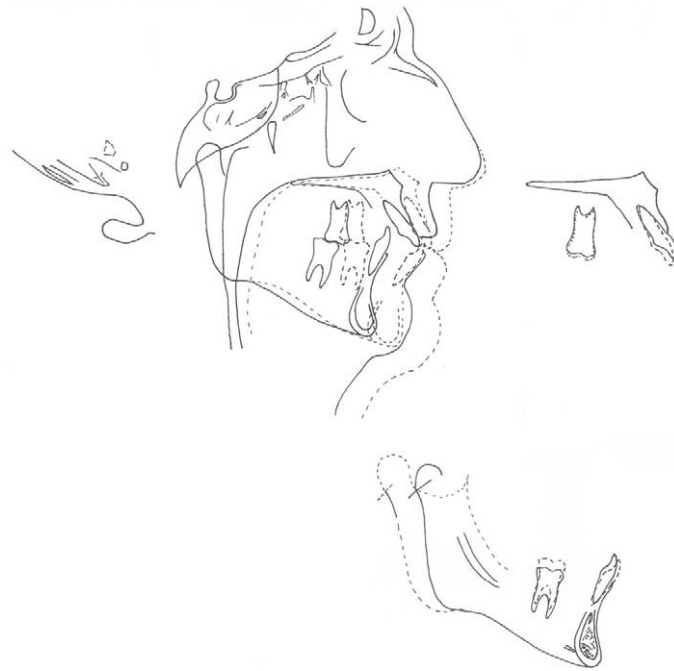

Fig 12. Superimposition of pretreatment and posttreatment lateral cephalometric radiographs.

distraction. The potential complications of segmental surgery include trauma to the teeth adjacent to the osteotomy and a much higher chance of “kinking” and or traumatizing the maxillary pedicle. Any vascular compromise might lead to loss of at least 1 maxillary segment. A smaller segment size increases the risk of segment necrosis due to vascular insufficiency.

Because the segmental expansion of the maxilla produces less expansion, an inadequate transverse dimension would have been created that would not have allowed for mandibular transverse expansion. Without the mandibular transverse distraction osteogenesis, less oral volume would have been created. Only an anteroposterior volume increase resulting from the mandibular advancement would have been produced. With the bimaxillary transverse distraction, both anteroposterior and transverse increases were created in both arches. Creating a larger oral volume provides more room to accommodate the tongue, thus bringing the base of the tongue farther from the posterior pharyngeal wall, opening up the oropharynx.

The advantage of the segmental LeFort I osteotomy over maxillary transverse distraction osteogenesis is that the surgery is done in a single stage. For this patient, mandibular distraction was required as a first stage, so 2 stages of surgery were required. Overall, if significant maxillary expansion is required, maxillary transverse distraction osteogenesis is the preferred procedure.

In patients with severe OSA and Class I occlusions, it has been reported that maxillary and mandibular advancements less than 10 mm are associated with less successful or incomplete resolution of the symptoms.<sup>19</sup> In patients with severe Class II malocclusions, it can be more difficult to advance the maxilla as much as desired because an impractical amount of mandibular advancement can be required. To merely maintain the underlying severe Class II relationship, the mandible must be advanced the same amount that the maxilla is advanced. To correct the malocclusion at the same time as addressing the OSA, the mandible must be advanced an additional amount to correct the underlying mandibular hypoplasia. A full-cusp Class II typically requires approximately 7 mm of mandibular advancement if the maxilla remains stationary. If the maxilla is advanced 10 mm, the mandible must be brought forward approximately 17 mm to achieve a Class I relationship. Because of his severe Class II relationship, to address both the sleep apnea and the underlying malocclusion, this patient underwent a maxillary advancement of approximately 10 mm and a mandibular advancement of approximately 18 mm.

As mentioned earlier, no attempt was made to use the space obtained from the mandibular transverse distraction osteogenesis to correct the Class II malocclusion. By not correcting the Class II relationship, the patient was left with a slightly greater than full-cusp

Class II molar and canine relationship. The larger mandibular advancement produces additional improvement in OSA because the muscular attachments advance with the mandible. As the genioglossus and geniohyoid muscles are brought forward, the chance of airway compromise from the tongue falling back during sleep decreases. Even minimal improvement of the Class II relationship presurgically would have decreased the amount of surgical mandibular advancement and the associated muscular improvement.

## CONCLUSIONS

The role of the transverse dimension in OSA is not yet fully understood. Initial information is beginning to be seen in the literature, but only a few patients with relatively mild sleep apnea have been reported. This case report illustrates the tremendous functional benefit of increasing the transverse and the anteroposterior dimensions in a patient with OSA. Future studies will illustrate objective improvement in the symptoms associated with severe OSA with overnight polysomnography test results after expansion. Maxillomandibular transverse distraction osteogenesis followed by maxillomandibular advancement might be an even more effective form of treatment for patients with severe OSA than maxillomandibular advancement alone.

We would like to thank Dr Scott B. Boyd, Professor and Chairman of Oral and Maxillofacial Surgery at Vanderbilt University Medical Center, for the necessary surgical expertise. His assistance in maximizing the patient's esthetic, functional, and occlusal improvements was invaluable.

## REFERENCES

1. Strollo PJ Jr, Rogers RM. Obstructive sleep apnea. *N Engl J Med* 1996;11;33:99-104.
2. Young T, Palta M, Dempsey J, Skatrud J, Weber S, Badr S. The occurrence of sleep-disordered breathing among middle-aged adults. *N Engl J Med* 1993;328:1230-5.
3. Smith PL, Gold AR, Meyers DA, Handnick EF, Bleecker ER. Weight loss in mildly to moderately obese patients with obstructive sleep apnea. *Ann Intern Med* 1985;103:850-5.
4. Scrima L, Broody M, Nay KN, Cohn MA. Increased severity of obstructive sleep apnea after bedtime alcohol ingestion: diagnosis and potential and proposed mechanisms of action. *Sleep* 1982;5:318-28.
5. Sanders MH, Moore SE, Eveslance J. CPAP via nasal mask: a treatment for obstructive sleep apnea. *Chest* 1983;83:144-5.
6. Coleman JA Jr. Laser-assisted uvulopalatoplasty: long-term results with a treatment for snoring. *Ear Nose Throat J* 1998;77:22-34.
7. Prinsell JR. Maxillomandibular advancement surgery for obstructive sleep apnea syndrome. *J Am Dent Assoc* 2002;133:1489-97.
8. Conley R, Legan H. Mandibular symphyseal distraction osteogenesis: diagnosis and treatment planning considerations. *Angle Orthod* 2003;73:3-11.
9. Conley RS, Legan HL. Correction of severe vertical maxillary excess with anterior open bite and transverse maxillary deficiency. *Angle Orthod* 2002;72:265-74.
10. Pirelli P, Saponara M, Guilleminault C. Rapid maxillary expansion in children with obstructive sleep apnea syndrome. *Sleep* 2004;27:761-6.
11. Cistulli PA, Palmisano RG, Poole MD. Treatment of obstructive sleep apnea syndrome by rapid maxillary expansion. *Sleep* 1998;21:831-5.
12. Bell WH, Epker BN. Surgical-orthodontic expansion of the maxilla. *Am J Orthod* 1976;70:517-28.
13. Frost HM. Regional acceleratory phenomenon: a review. *Henry Ford Hosp Med J* 1983;31:3-9.
14. Waite PD, Shettar SM. Maxillomandibular advancement: a cure for obstructive sleep apnea. *Oral Maxfac Surg Clin North Am* 1995;7:327-36.
15. Kunkel M, Hochban W. The influence of maxillary osteotomy on nasal airway patency and geometry. *Mund Kiefer Gesichtschir* 1997;1:194-8.
16. Courtiss EH, Goldwyn RM. The effects of nasal surgery on airflow. *Plast Reconstr Surg* 1983;72:9-21.
17. Silverstein K, Quinn PD. Surgically assisted rapid palatal expansion for management of transverse maxillary deficiency. *J Oral Maxillofac Surg* 1997;55:725-7.
18. Bailey LJ, White RP, Proffit WR, Turvey TA. Segmental LeFort I osteotomy for management of transverse maxillary deficiency. *J Oral Maxillofac Surg* 1997;55:728-31.
19. Hochban W, Brandenburg U, Peter JH. Surgical treatment of obstructive sleep apnea by maxillomandibular advancement. *Sleep* 1994;17:624-9.